



Dentoskeletal Effects of the Modified Tandem Appliance vs the Facemask Appliance in the Treatment of Skeletal Class III Malocclusion: A Single-center, Randomized Controlled Trial

¹Amro H Husson, ²Ahmad S Burhan, ³Fadwa B Salma, ⁴Fehmieh R Nawaya

ABSTRACT

Aims: The aim of this randomized controlled trial was to compare the skeletal and dentoalveolar effects of the modified tandem appliance (MTA) vs the facemask (FM) with rapid maxillary expansion.

Materials and methods: Thirty-two patients, aged 7 to 9 years were recruited. Eligibility criteria included skeletal class III malocclusion that resulted from the retrusion of the maxilla. Randomization was accomplished to divide the sample into two equal groups to be treated with either MTA or FM. Lateral cephalometric radiographs were obtained before treatment and after 2 mm positive overjet was achieved. Intragroup comparisons were performed using paired-sample t-test, and intergroup comparisons were performed using two-sample t-test at the $p \leq 0.05$ level.

Results: Thirty-two patients (16 in each group) were available for statistical analysis. The pretreatment variables of both groups were similar. Both treatment therapies showed similar significant increase in the SNA and ANB angles, accompanied by slight decrease in the SNB angle. The increase in the SN:GoMe angle, Bjork's sum, and the overjet were significantly greater in the FM group. The forward movement of upper dentition was similar in both groups. Although the lower incisors retrusion was significantly greater in the FM group than in the MTA group, the uprighting of the lower molars was significantly greater in the MTA group.

Conclusion: Both appliances showed similar effects apart from less clockwise rotation of the mandible, less retrusion of

the lower incisors, and greater uprighting of the lower molars in the MTA group.

Clinical significance: Both the MTA and the FM groups are effective in treating class III malocclusion. The MTA group is more efficient in controlling the clockwise rotation and gaining some space in the lower arch.

Keywords: Class III treatment, Facemask, Modified tandem appliance, Randomized clinical trial.

How to cite this article: Husson AH, Burhan AS, Salma FB, Nawaya FR. Dentoskeletal Effects of the Modified Tandem Appliance vs the Facemask Appliance in the Treatment of Skeletal Class III Malocclusion: A Single-center, Randomized Controlled Trial. *J Contemp Dent Pract* 2016;17(7):522-529.

Source of support: Nil

Conflict of interest: None

INTRODUCTION

Skeletal class III malocclusions may include a protrusive mandible, a retrusive maxilla, or a combination of both.¹ When abnormality is located in maxilla, treatment strategy involves stimulation and guidance of maxillary growth by orthopedic forces.² Therefore, protraction of the maxilla with extraoral appliances, such as, facemasks (FMs) and reverse-pull headgears has been recommended for growing class III patients with maxillary retrusion.³

Treatment effects of such appliances were reported by several clinical studies as forward movement of the maxilla and maxillary dentition; often accompanied by backward movement and a clockwise rotation of the mandible and with backward movement of the mandibular dentition.^{1,2,4-7}

¹⁻³Department of Orthodontics, Faculty of Dentistry, Damascus University, Damascus, Syrian Arab Republic

⁴Department of Pediatric Dentistry, Faculty of Dentistry, Syrian Private University, Damascus Countryside, Syrian Arab Republic

Corresponding Author: Ahmad S Burhan, Associate Professor, Department of Orthodontics, Faculty of Dentistry Damascus University, Damascus, Syrian Arab Republic, Phone: +963944302075, e-mail: dr.burhan-a@hotmail.com

Despite the FM efficiency in treating maxillary deficiency is proved, the physical appearance and bulkiness of this extraoral appliance reduce patients' cooperation and motivation, which decrease its clinical effects.⁸

Many intraoral appliances have been used to correct maxillary deficiency as alternative procedure to the FM therapy due to its poor esthetics. However, comparisons of functional orthopedic appliances with FM demonstrated that FM is most effective in correcting maxillary deficiency.^{5,9}

The tandem traction bow appliance (TTBA) designed by Chun was defined as an esthetic and comfortable intraoral appliance.^{10,11} Clinical studies of modified TTBA (MTTBA) found similar treatment effects of both the FM and the MTTBA.^{8,12}

Recently, Klempner¹³ introduced the modified tandem appliance (MTA), which is more patient-friendly and simpler than the earlier one. In a published case report, Klempner¹⁴ suggested that MTA was effective in the treatment of class III malocclusion.

To the best of author's knowledge, there is not any study comparing the skeletal and dental effects of the MTA and the FM.

Specific Objectives and Hypotheses

The aim of this randomized controlled trial was to compare the skeletal and dentoalveolar effects of the MTA vs the FM in treating patients with class III malocclusion. It aimed to test the null hypothesis saying that there are no significant differences of hard tissue and dental changes induced by the MTA and the FM.

MATERIALS AND METHODS

Trial Design

The research was designed as a single-center two-arm parallel-group randomized controlled trial with a 1:1 allocation ratio.

Participants, Eligibility Criteria, and Setting

Participants were screened from the patients who were seeking treatment at the Department of Orthodontics, Damascus University, and then they were invited to participate. Patients who matched the following inclusion criteria were selected: Patients in early mixed dentation; class III molar relationship; anterior crossbite or edge-to-edge incisal relationship; ANB angle of 0° or less; and A-point to the perpendicular on FH from Nasion of 1 mm or less; no extracted or congenitally missing teeth; no deformity in the nasomaxillary complex; normal or horizontal growth pattern (Bjork's sum = 396° - 5°), and no history of temporomandibular disorders.

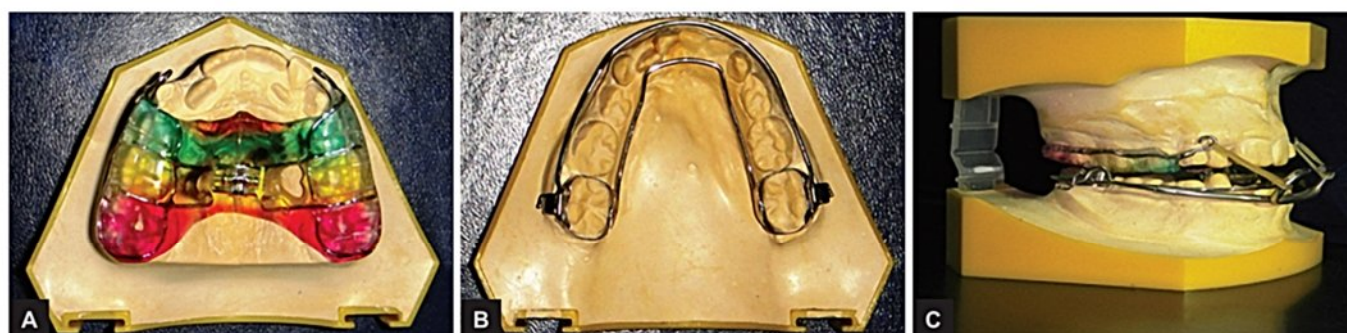Ethical approval from the Regional Ethical Committee of Damascus University, Faculty of Dentistry and informed consent from the parents of the children were obtained.

Interventions

Group I consisted of 16 patients (8 males and 8 females; mean age 7.98 ± 0.68 years) treated using the MTA. The MTA used in this study has three components; two fixed and one removable. The upper fixed one composed of bonded maxillary expander, with 2 mm posterior acrylic splint to release upper dentition from occlusion. Buccal arms for elastic traction were added distally to the primary lateral incisors (Fig. 1A). Lower appliance comprised fixed buccal and lingual arches with buccal headgear tubes (Fig. 1B). Flowable composite had been added between the buccal surfaces of second primary lower molars and the buccal wire to increase anchorage. A 0.045" headgear facebow with the outer bows bent out for elastic attachment is inserted into the lower tubes (Fig. 1C).

Group II (FM group) consisted of 16 patients (7 males and 9 females; mean age 8.11 ± 0.76 years) treated using the Petit-type FM (Multi-Adjustable Facemask, Ortho Technology, Lutz, Florida) and the same bonded maxillary expander of the group I (Fig. 2).

All patients were treated by two researchers; the first group was treated by (AH) while the second one



Figs 1A to C: The MTA appliance used in the study: (A) The bonded maxillary plate with an expander; (B) the double buccal and lingual arch with buccal headgear tubes; and (C) the headgear facebow and intermaxillary elastics in place

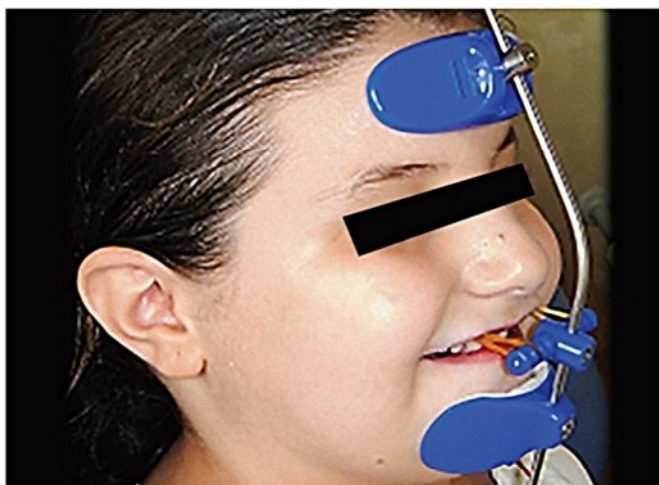

Fig. 2: Petit-type FM used in the study

by (FS) at the same postgraduate orthodontic clinic of Damascus University. Unified method of expansion and elastic traction was used in both groups. The screw of maxillary expander was activated twice a day until palatal suture was opened in cases without posterior crossbite. However, activation was continued until the crossbite was overcorrected in cases with posterior crossbite. Initial protraction force of 8 oz (230 g) per side was applied with an anteroinferior force vector of approximately 30° to the occlusal plane for 6 weeks, followed by 14 oz (400 g) elastic force until a 2-mm positive overjet was achieved. In both groups, patients were instructed to wear their appliances at least 16 hours per day.

Outcomes and Changes after Trial Commencement

Lateral cephalometric radiographs were taken using the same X-ray machine (Planmeca; Planmeca Oy, Helsinki, Finland) at the beginning of the treatment (T0) and after obtaining an adequate overjet of 2 mm (T1). All radiographs were taken in a standard patients' position in the cephalostat, where their teeth in occlusion and their lips were relaxed. All the cephalograms of both the groups were manually traced and measured by one investigator (AH). In addition to SN and Frankfort planes, horizontal reference plane T-W (T: The most superior point of the anterior wall of the sella turcica at the junction with tuberculum sella; W: The point at which the middle cranial fossa is intersected by the sphenoid bone) and vertical reference line (a vertical line perpendicular to T-W at T point) were adopted from the study of Atalay and Tortop.⁸ Eighteen linear and six angular parameters were evaluated. The landmarks and the measurements used in the present study are shown in Figures 3 and 4 respectively.

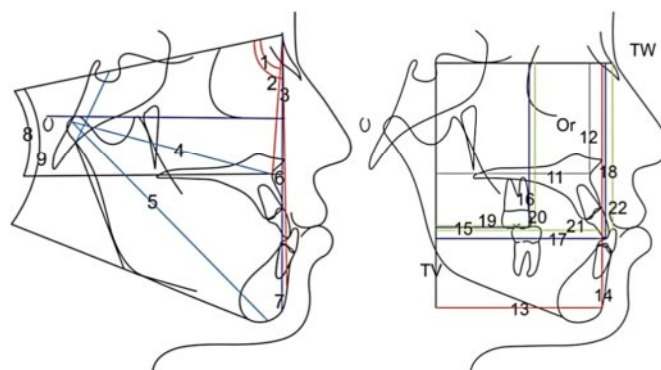


Fig. 3: Cephalometric landmarks used in the present study

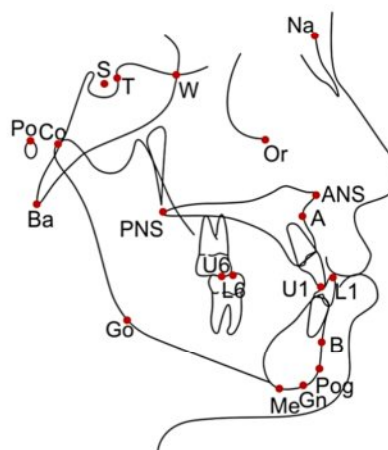


Fig. 4: Skeletal and dental measurements used in the study: 1 – SNA ($^\circ$), 2 – SNB ($^\circ$), 3 – ANB ($^\circ$), 4 – CoA (mm), 5 – CoGn (mm), 6 – N \perp FH-A (mm), 7 – N \perp FH-Pog (mm), 8 – SN:SPP ($^\circ$), 9 – SN:GoMe ($^\circ$), 11 – point A-TV (mm), 12 – point A-TW (mm), 13 – Pog-TV (mm), 14 – Pog-TW (mm), 15 – upper molar-TV (mm), 16 – upper molar-TW (mm), 17 – upper incisor-TV (mm), 18 – upper incisor-TW (mm), 19 – lower molar-TV (mm), 20 – lower molar-TW (mm), 21 – lower incisor-TV (mm), 22 – lower incisor-TW (mm)

Sample Size Estimation

The sample size was established using G*Power software, version 3.0.10 (Franz Faul, Universität Kiel, Germany) with two-sample t tests, a selected study power of 85%, a significance level of 0.05, and allocation ratio of 1:1. The effect size was calculated according to the study of Tortop et al¹² and basing on the values of the SNA angle. The analysis showed that 30 patients were required. Two patients were added to compensate for the potential dropouts.

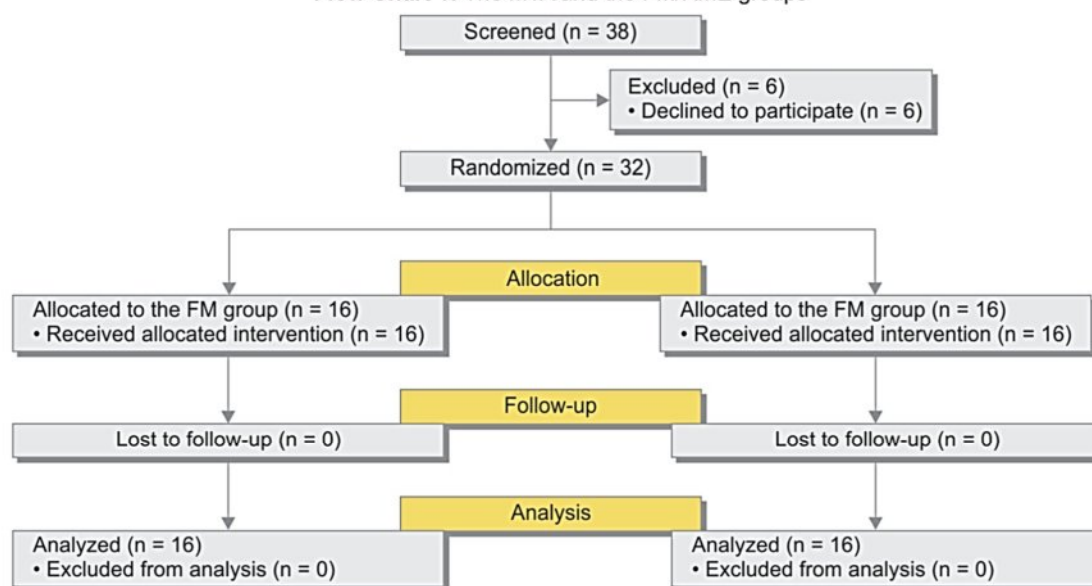
Randomization

Patients who met the inclusion criteria were randomized in a 1:1 ratio into two equal groups using an online randomization service (www.randomizer.org).¹⁵

Blinding

Blinding of either patient or operator was not possible; it was applicable for the outcome assessment only. The group to which each patient belonged to was unknown when the radiographs were traced and measured.

Flow Chart 1: The MTA and the FM/RME groups



Method Error

To determine the errors associated with tracings and measurements, 15 lateral radiographs were retraced and remeasured at least after 30 days. Paired-sample t-test showed no significant differences between the two measurements. The overall errors were calculated using the formula of Dahlberg.¹⁶ The method errors revealed that the error of the various measurements did not exceed 0.5 mm and 0.6°.

STATISTICAL ANALYSIS

The data were analyzed using Statistical Package for the Social Sciences (SPSS) software, version 20 (IBM SPSS Statistics, IBM Corp., Armonk, USA). Kolmogorov–Smirnov test was performed on the data, and they were found to be normally distributed. Therefore, intragroup comparisons were evaluated by means of paired-sample t-test, and intergroup comparisons were analyzed by means of two-sample t-test. All results were judged at the $p \leq 0.05$ level.

RESULTS

Participant Flow

Initially, 38 patients' data with skeletal class III were examined. Six patients did not fulfill the inclusion criteria. Thirty-two patients (15 males and 17 females) were randomly divided into two equal groups. All patients completed the treatment and were available for the statistical analysis. Patient recruitment commenced in May 2014 and ended in August 2014; the patient flow diagram of the MTA and the FM groups is shown in Flow Chart 1.

Table 1: Comparison of the groups regarding initial age and treatment period

	MTA group		FM group		p-value
	Mean	SD	Mean	SD	
Initial age (years)	7.98	0.68	8.11	0.76	0.633
Treatment period (months)	7.07	0.78	6.4	1.30	0.101

Baseline Data

The initial ages and treatment period of the MTA and FM groups are shown in Table 1. Mean treatment periods were 7.07 0.78 and 6.4 1.30 months respectively. The results of two-sample t-test showed no statistically significant difference between the two groups.

Statistical comparison of the pretreatment values between the MTA and the FM groups showed no significant differences between the groups apart from the distance between upper incisor to the TV ($p \leq 0.05$; Table 2).

Numbers analyzed for Each Outcome

Intragroup and intergroup comparisons are shown in Table 3.

Skeletal Changes

Many significant changes occurred in both the MTA and the FM groups, including anterior displacement of the maxilla. The SNA angle increased by 1.38° ($p < 0.001$) and 1.5° ($p < 0.001$) respectively, without significant difference between the two groups ($p = 0.567$). The distance from A point to TV increased by 1.31 mm ($p < 0.001$) and 1.56 mm ($p < 0.001$) respectively, without significant difference between the two groups ($p = 0.331$). The

Table 2: Pretreatment mean and standard deviation (SD) values and statistical differences between the groups

Skeletal and dental variables	MTA group (n=16)		FM group (n=16)		p-value
	Mean	SD	Mean	SD	
SNA (dg)	78.31	2.09	77.06	2.21	0.11
SNB (dg)	79.25	2.08	78.31	1.92	0.20
ANB (dg)	-0.88	0.72	-1.25	0.77	0.17
CoA (mm)	81.88	4.60	80	3.72	0.215
CoGn (mm)	106.38	1.67	105.25	2.70	0.168
N \perp FH-A (mm)	-1.81	1.15	-2.5	1.65	0.055
N \perp FH-Pog (mm)	-1.38	0.96	-1.69	1.08	0.393
SN/SPP (dg)	7.06	1.48	6.75	1.65	0.58
SN/GoMe (dg)	32.94	2.67	34	3.39	0.33
Bjork's sum (dg)	389.69	5.04	390.25	5.64	0.77
PointA-TV (mm)	47.81	2.83	47.94	3.32	0.91
PointA-TW (mm)	48.44	4.59	49.56	2.76	0.41
Pog-TV (mm)	47.50	3.25	47.13	3.10	0.74
Pog-TW (mm)	95.56	6.31	95.81	5.80	0.91
Uppermolar-TV (mm)	19.50	2.13	18.5	2.34	0.22
Uppermolar-TW (mm)	56.75	4.19	56.25	4.40	0.74
Upperincisor-TV (mm)	57.56	3.85	60.94	5.20	0.05*
Upperincisor-TW (mm)	62.56	3.93	62	4.20	0.70
Lowermolar-TV (mm)	18.81	3.29	17.38	3.48	0.24
Lowermolar-TW (mm)	59.94	4.06	62.25	2.96	0.08
Lowerincisor-TV (mm)	53.31	6.16	50.69	6.04	0.23
Lowerincisor-TW (mm)	63.19	5.98	65.25	5.95	0.34
Overjet (mm)	-1.87	1.31	-1.56	0.96	0.448
Overbite (mm)	1.38	0.96	1.44	0.96	0.855

*p<0.05

Table 3: Mean and standard deviation (SD) values of treatment changes and statistical differences between the groups

Skeletal and dental variables	MTA group (n=16)			FM group (n=16)			p-value
	Mean	SD	p-value	Mean	SD	p-value	
SNA (dg)	1.38	0.62	<0.001***	1.5	0.63	<0.001***	0.576
SNB (dg)	-0.44	0.51	0.001	-0.69	0.70	<0.001***	0.26
ANB (dg)	1.88	0.72	<0.001***	2.13	1.09	<0.001***	0.449
CoA (mm)	1.25	1.67	0.018*	1.38	2.21	0.018**	0.859
CoGn (mm)	1.13	1.88	0.017*	1.25	2.06	0.039*	0.858
N \perp FH-A (mm)	1.56	0.82	<0.001***	1.88	0.93	<0.001***	0.485
N \perp FH-Pog (mm)	-0.44	0.63	0.014*	-0.88	0.81	<0.001***	0.098
SN/SPP (dg)	-0.31	0.60	0.08	-0.38	0.62	0.02*	0.774
SN/GoMe (dg)	1.00	0.97	<0.001***	3.5	1.41	<0.001***	<0.001***
Bjork's sum (dg)	2.38	1.54	<0.001***	4.69	2.02	<0.001***	<0.001***
PointA-TV (mm)	1.31	0.48	<0.001***	1.56	0.89	<0.001***	0.331
PointA-TW (mm)	0.88	0.62	<0.001***	1	0.82	<0.001***	0.629
Pog-TV (mm)	-0.69	0.48	<0.001***	-1.31	0.70	<0.001***	0.006**
Pog-TW (mm)	1.06	0.57	<0.001***	2.31	0.70	<0.001***	<0.001***
Uppermolar-TV (mm)	0.56	0.51	<0.001***	0.94	0.77	<0.001***	0.116
Uppermolar-TW (mm)	0.94	0.85	<0.001***	0.88	0.50	<0.001***	0.802
Upperincisor-TV (mm)	1.12	0.96	<0.001***	1.25	0.93	0.02*	0.711
Upperincisor-TW (mm)	1.19	0.98	<0.001***	1.38	1.02	0.001***	0.601
Lowermolar-TV (mm)	-0.75	0.45	<0.001***	-0.31	0.48	0.02*	0.012**
Lowermolar-TW (mm)	-0.63	0.50	<0.001***	-0.56	0.51	<0.001***	0.729
Lowerincisor-TV (mm)	-1.25	0.68	<0.001***	-2.31	1.35	<0.001***	0.009**
Lowerincisor-TW (mm)	-1	1.10	<0.001***	-1.18	1.11	<0.001***	0.634
Overjet (mm)	2.25	1.45	<0.001***	3.53	1.24	<0.001***	0.04*
Overbite (mm)	-0.4	0.81	0.048*	-1.76	0.50	<0.001***	0.01**

*p < 0.05; **p < 0.01; ***p < 0.001

distance from A point to N₁FH increased by 1.56 mm ($p < 0.001$) and 1.88 mm ($p < 0.001$) respectively, without significant difference between the two groups ($p = 0.485$).

The SN:SPP angle significantly decreased by -0.38° ($p = 0.02$) in the FM group, and by -0.31° ($p = 0.08$) in the MTA group, without significant difference between the two groups ($p = 0.774$).

The mandible displaced backward; the SNB angle decreased by -0.44° ($p < 0.001$) and -0.69° ($p < 0.001$) respectively, without significant difference between the two groups ($p = 0.26$). However, the distance from Pog point to TV decreased by -0.69 mm ($p < 0.001$) and -1.31 mm ($p < 0.001$) in the MTA group and the FM group respectively, and this decrease was significantly larger in the FM group than in the MTA group ($p = 0.006$).

Both groups showed clockwise rotation. The SN:GoMe angle significantly increased by 1° ($p < 0.001$) and 3.5° ($p < 0.001$) in the MTA group and the FM group respectively, and this increase was significantly larger in the FM group than in the MTA group ($p < 0.001$). The Bjork's sum significantly increased by 2.38° ($p < 0.001$) and 4.69° ($p < 0.001$) in the MTA group and the FM group respectively, and this increase was significantly larger in the FM group than in the MTA group ($p < 0.001$).

The mandible length significantly increased in both treatment groups; Co-Gn increased by 1.13 mm ($p = 0.017$) and 1.25 mm ($p = 0.039$) in the MTA group and the FM group respectively, without significant difference between the two groups ($p = 0.858$).

The combined displacement of the maxilla and the mandible led to a significant improvement in the intermaxillary sagittal relationship; the ANB angle increased in both the MTA group and the FM group by 1.88° ($p < 0.001$) and 2.13° ($p < 0.001$) respectively, without significant difference between the two groups ($p = 0.449$).

Dental Changes

The maxillary incisors were significantly proclined by 1.12 mm ($p < 0.001$) and 1.25 mm ($p = 0.02$) in the MTA group and the FM group respectively, without significant differences between the groups ($p = 0.711$). The upper molars were mesially drift by 0.56 mm ($p < 0.001$) and 0.94 mm ($p < 0.001$) in the MTA group and the FM group respectively, without significant differences between the groups ($p = 0.116$).

The mandibular incisors retroclined by -1.25 mm ($p < 0.001$) and -2.31 mm ($p < 0.001$) in the MTA group and the FM group respectively, and these retroclinations were significantly larger in the FM group than in the MTA group ($p = 0.009$). The lower molars were distally moved by -0.75 mm ($p < 0.001$) and -0.31 mm ($p = 0.02$) in the MTA group and the FM group respectively. This

movement was significantly larger in the MTA group ($p = 0.012$).

The overjet significantly improved by 2.25 mm ($p < 0.001$) and 3.53 mm ($p < 0.001$) in the MTA group and the FM group respectively, without significant differences between the groups ($p = 0.07$). The overjet significantly increased by 2.25 mm ($p < 0.001$) and 3.53 mm ($p < 0.001$) in the MTA group and the FM group respectively, and this increase was significantly larger in the FM group than in the MTA group ($p = 0.04$). The overbite significantly decreased by -0.4 mm ($p = 0.048$) and -1.76 mm ($p < 0.001$) in the MTA group and the FM group respectively, and this decrease was significantly larger in the FM group than in the MTA group ($p = 0.01$).

Harms

No serious harm was observed.

DISCUSSION

To the best of author's knowledge, this is the first study comparing the skeletal and dental effects of the MTA and the FM in growing class III maxillary retrognathic patients.

The current study did not include untreated class III malocclusion group because of the unjustifiable repeated radiographic records and to avoid delaying the treatment of those patients. In addition, previous studies included an untreated class III and showed no statistical skeletal changes in the control group during the observation period, apart from a few linear measurements. For example, the study of Atalay and Tortop,⁸ and of Tortop et al,¹² showed only significant increase in Co-A, Co-Me, and ANS-me (mm) in the control group. Moreover, comparing the changes of these parameters showed insignificant differences between the treated and control groups. Similarly, our findings showed that the mandible length (Co-Gn) increased significantly for both FM and MTA groups, which is in accordance with the previous studies. These findings may imply that the treating appliances cannot prevent the increase of the mandibular length.

In the current work, the lower plate in the original tandem appliance was replaced by fixed buccal and lingual wires. In addition, some light-cured composite was used to fixate the wires to the second primary molars, which produces more anchorage than removable plate and distributes the applied forces to the whole mandibular dentition. This small and fixed lower part gives patients more comfort and increases patients' cooperation. The current design makes the maxillary part of the MTA similar to the maxillary part of the FM, which reduces the confounding factors and enables precise comparison between the two appliances.

Rapid maxillary expansion (RME) has been recommended by many researchers to disarticulate the circum-maxillary sutures, and consequently, to facilitate the anterior displacement of maxilla.^{17,18} In the present study, RME was used to disarticulate the circum-maxillary sutures and to release the posterior crossbites if they were found.

Skeletal Changes

The maxilla was similarly moved anteriorly in both treatment groups. These changes have been reported in relevant clinical studies.^{6-8,11,12,19,20} Lee et al²¹ found greater movements in the basal maxilla than those observed in the current research, which may be attributed to using skeletal anchorage in their study. However, the literature reported a large range of responses, from 1 to 4 mm.⁴ The design of appliances, the force level used, and the number of worn hours per day might be seriously affecting factors.²² In addition, the amount of skeletal movement is affected by the amount of dental movement, because we generally treat until a positive overjet is achieved.²³

Palatal plane was totally rotated anteriorly in both groups, but it was only significant in the FM group. However, the intergroup comparison of the vertical position of the maxilla did not show any significant difference between the groups. Although we agreed with many previous studies,^{6-8,11,19} our study disagreed with that of Kama which found clockwise rotation of the maxilla (approximately 1.5°) after FM treatment.²⁰ Palatal rotation might be caused by the protraction forces which were passed below the center of resistance of the maxilla and directed downward and forward, and led to lower the posterior side of the maxilla more than the anterior one.²³

In the present study, the mandible displaced backward and downward in both groups. However, comparing between groups indicated that the FM caused more increase in the vertical dimension than the MTA. The clockwise rotation of the mandible produced by the FM has been reported in relevant studies.^{5-7,22} Our findings showed that the MTA was doubtful in controlling the vertical dimensions, which disagrees with what Atalay and Tortop⁸ and Klempner¹⁴ indicated about the ability of the MTA to control the vertical dimension. On the contrary, Tortop et al¹² found similar effects of the FM and the MTTBA in vertical dimension. Although, the mandible length (Co-Gn) increased significantly in both treatment groups, this increase could be a reflection of growth rather than a direct result of treatment.²⁴

Dental Changes

The protraction force produced forward movement of the upper dentition in both groups. Intergroup comparison did not show any significant difference between the groups.

Contrary to the findings of the present study, Tortop et al¹² found significant difference between the MTTBA and FM groups in the movement of upper incisors.

Our findings showed that although both the upper molars and the A point moved anteriorly, this movement was lesser at the A point. These results can be attributed to the fact that A point is strongly affected by the axis and position of upper incisors, which moved anteriorly in the current study. These findings are in accordance with those of Tortop et al¹² and Atalay and Tortop.⁸

Although, the retrusion of the lower incisors was observed in both treatment groups, it was greater in the FM group. This difference between the groups might be due to the lingual arch used in the MTA group and the direct force applied from the chin cap of the FM to the lower incisors. The results of previous studies that used mandibular plates support our findings.^{20,25,26}

In the MTA group, the lower molars were uprighted more than those in the FM group. Our findings agreed with the studies of Atalay and Tortop⁸ and Tortop et al.¹² In contrast, Kim et al¹¹ found a forward movement in lower molars (0.87 mm). In our study, the uprighting of the lower molars may be attributed to the direct force applied to the lower molars from the facebow.

The overjet significantly increased and the overbite significantly decreased in both treatment groups. These changes were significantly greater in the FM group. Tortop et al¹² pointed out that the upper incisor inclination was the reason of the difference in the overjet between MTTBA and FM. In this study, the greater retroclination of lower incisors and the clockwise rotation of the mandible observed in the FM group seemed to be responsible for the difference in the overjet and the overbite between the groups.

Limitations

This study has two limitations, one of which is a short-term observation period. Long-term studies are needed to evaluate the stability of the results. Another limitation is lack of an untreated control group, which means that the changes are attributed to both treatment and ordinary growth. However, the differences between the groups can be attributed to the appliance differences, which fulfill the aim of the current study.

Generalizability

It is important to compare the patients with similar ages, dentoskeletal patterns, and treatment periods, which may affect the results of maxillary protraction.^{19,21} In the current study, there were not statistically significant differences regarding these parameters between the groups. In addition, the mean age of groups was in

early optimal class III treatment timing (approximately 8 years).^{19,27} These factors emphasize the generalizability of the current research findings.

CONCLUSION

- Both the MTA and the FM induce significant forward movement to the maxilla and slight backward movement to the mandible.
- The FM causes more clockwise rotation to the mandible than the MTA.
- Both appliances lead to significant protrusion in the upper dentition and significant retrusion in the lower dentition.
- The FM causes greater lower incisors retrusion, while the MTA causes greater uprighting of the lower molars, which may be useful in decrowding the lower arch.

CLINICAL SIGNIFICANCE

Both the MTA and the FM are effective in treating class III malocclusion. The MTA is preferable compared to the FM when clockwise rotation is not desirable, and uprighting of the lower molars is required for solving mild crowding in the lower arch.

Registration: This trial was registered at <https://clinicaltrials.gov>.

Protocol: The protocol was published before the trial commencement. Identifier: NCT02144324.

REFERENCES

1. Toffol LD, Pavoni C, Baccetti T, Franchi L, Cozza P. Orthopedic treatment outcomes in Class III malocclusion: a systematic review. *Angle Orthod* 2008 May;78(3):561-573.
2. Kim JH, Viana MA, Graber TM, Omerza FF, BeGole EA. The effectiveness of protraction face mask therapy: a meta-analysis. *Am J Orthod Dentofacial Orthop* 1999 Jun;115(6):675-685.
3. Fields H, Proffit W. Treatment of skeletal problems in children. In: Proffit W, Fields H, Sarver D, editors. *Contemporary orthodontics*. 4th ed. St. Louis, Missouri: Mosby; 2007. p. 495-511.
4. Cordasco G, Matarese G, Rustico L, Fastuca S, Caprioglio A, Lindauer SJ, Nucera R. Efficacy of orthopedic treatment with protraction facemask on skeletal Class III malocclusion: a systematic review and meta-analysis. *Orthod Craniofac Res* 2014 Aug;17(3):133-143.
5. Godt A, Zeyher C, Schatz-Maier D, Goz G. Early treatment to correct Class III relations with or without face masks. *Angle Orthod* 2008 Jan;78(1):44-49.
6. Vaughn GA, Mason B, Moon H-B, Turley PK. The effects of maxillary protraction therapy with or without rapid palatal expansion: a prospective, randomized clinical trial. *Am J Orthod Dentofacial Orthop* 2005 Sep;128(3):299-309.
7. Mandall N, DiBiase A, Littlewood S, Nute S, Stivaros N, McDowall R, Shargill I, Worthington H, Cousley R, Dyer F, et al. Is early Class III protraction facemask treatment effective? A multicentre, randomized, controlled trial: 15-month follow-up. *J Orthod* 2010 Sep;37(3):149-161.
8. Atalay Z, Tortop T. Dentofacial effects of a modified tandem traction bow appliance. *Eur J Orthod* 2010 Dec;32(6):655-661.
9. Seehra J, Fleming PS, Mandall N, Dibiase AT. A comparison of two different techniques for early correction of Class III malocclusion. *Angle Orthod* 2012 Jan;82(1):96-101.
10. Chun YS, Jeong SG, Row J, Yang SJ. A new appliance for orthopedic correction of Class III malocclusion. *J Clin Orthod* 1999 Dec;33(12):705-711.
11. Kim H-J, Chun Y-S, Lim WH. Maxillary protraction effects of TTBA (tandem traction bow appliance) therapy in Korean Class III children. *Korean J Orthod* 2007 Jun;37(3):231-240.
12. Tortop T, Kaygisiz E, Gencer D, Yuksel S, Atalay Z. Modified tandem traction bow appliance compared with facemask therapy in treating Class III malocclusions. *Angle Orthod* 2014 Jul;84(4):642-648.
13. Klemptner LS. Early orthopedic Class III treatment with a modified tandem appliance. *J Clin Orthod* 2003 Apr;37(4):218-223.
14. Klemptner L. Early treatment of skeletal Class III open bite with the tandem appliance. *J Clin Orthod* 2011 Jun;45(6):308-316.
15. Urbaniak GC, Plous S. Research randomizer; 2014 [accessed 2014 Aug 23]. Available from: <http://www.randomizer.org/>.
16. Dahlberg G. *Statistical methods for medical and biological students*. London: George Allen and Unwin; 1940. p. 98.
17. Baccetti T, McGill JS, Franchi L, McNamara JA Jr, Tollaro I. Skeletal effects of early treatment of Class III malocclusion with maxillary expansion and face-mask therapy. *Am J Orthod Dentofacial Orthop* 1998 Mar;113(3):333-343.
18. Kurt G, Uysal T, Yagci A. Soft and hard tissue profile changes after rapid maxillary expansion and face mask therapy. *World J Orthod* 2010 Winter;11(4):e10-e18.
19. Baccetti T, Franchi L, McNamara JA Jr. Treatment and posttreatment craniofacial changes after rapid maxillary expansion and facemask therapy. *Am J Orthod Dentofacial Orthop* 2000 Oct;118(4):404-413.
20. Kama JD, Ozer T, Baran S. Orthodontic and orthopaedic changes associated with treatment in subjects with Class III malocclusions. *Eur J Orthod* 2006 Oct;28(5):496-502.
21. Lee NK, Yang IH, Baik SH. The short-term treatment effects of face mask therapy in Class III patients based on the anchorage device: miniplates vs rapid maxillary expansion. *Angle Orthod* 2012 Sep;82(5):846-852.
22. Turley PK. Managing the developing Class III malocclusion with palatal expansion and facemask therapy. *Am J Orthod Dentofacial Orthop* 2002 Oct;122(4):349-352.
23. Sayinsu K, Isik F, Arun T. Sagittal airway dimensions following maxillary protraction: a pilot study. *Eur J Orthod* 2006 Apr;28(2):184-189.
24. Ucuncu N, Ucem TT, Yuksel S. A comparison of chin-cap and maxillary protraction appliances in the treatment of skeletal Class III malocclusions. *Eur J Orthod* 2000 Feb;22(1):43-51.
25. Altug Z, Arslan AD. Skeletal and dental effects of a mini maxillary protraction appliance. *Angle Orthod* 2006 May;76(3):360-368.
26. Celikoglu M, Yavuz I, Unal T, Oktay H, Erdem A. Comparison of the soft and hard tissue effects of two different protraction mechanisms in class III patients: a randomized clinical trial. *Clin Oral Invest* 2015 Nov;19(8):2115-2122.
27. Kajiyama K, Murakami T, Suzuki A. Comparison of orthodontic and orthopedic effects of a modified maxillary protractor between deciduous and early mixed dentitions. *Am J Orthod Dentofacial Orthop* 2004 Jul;126(1):23-32.